

PATIENT

Leilah Beber

SPECIES

Canine

BREED

Havanese

SEX

FS

AGE

8 years

WEIGHT

20 #

INTERPRETED BY

Remo Lobetti, BVSc,
MMedVet (Med), PhD,
Dipl. ECVIM

IMAGING PERFORMED BY

Lisa Bancroft, DVM

HOSPITAL NAME

Treasure Coast Animal
Emergency

REFERRING VET

Dr Angela Cail

INVOICE

303720

DATE

12/30/22

PRESENTING CLINICAL SIGNS

History: Hematuria – non-response to antibiotic therapy.

Physical Examination: N/A.

Urinalysis: N/A.

CBC: N/A

Serum Biochemistry: N/A.

Radiographic Findings: N/A.

ULTRASONOGRAPHIC EXAMINATION OF THE ABDOMEN

Urinary System

Full urinary bladder with a thickened (0.4 cm) and irregular appearance of the wall. Small polyp-like lesions (0.5-0.8 cm) on the dorsal bladder wall in the region of the trigone with thickening of the underlying wall. Normal anechoic urine with no sediment evident. Multiple uroliths present.

Normal proximal urethra (0.3 cm) and iliac blood vessels.

Normal iliac lymph nodes. Ureters not visualized.

Normal renal size (left 4.1 cm, right 4.2 cm), echogenic appearance, cortico-medullary differentiation, pelvis, and capsule.

Reproductive System

N/A.

Adrenal Glands

Normal shape, echogenic appearance, position, and size. Left 0.41 cm, right 0.51 cm.

Spleen

Normal size and echogenic appearance. Smooth homogenous parenchyma, regular curvilinear capsule, and normal vasculature. No evidence of inflammatory, neoplastic, infarction, or infiltrative changes noted. Incidental myelolipoma (0.3 cm).

Liver

Normal size, with increased echogenic appearance, some loss of portal markings, and regular curvilinear capsule. Focal mottled echogenic parenchymal nodule in the left lateral lobe (1.4 x 2.0 cm). Full gall bladder containing small amount of hyperechogenic sediment. Normal thickness and echogenic appearance of the gall bladder wall. Normal bile duct.



PATIENT

Leilah Beber

SPECIES

Canine

BREED

Havanese

SEX

FS

AGE

8 years

WEIGHT

20 #

INTERPRETED BY

Remo Lobetti, BVSc,
MMedVet (Med), PhD,
Dipl. ECVIM

IMAGING PERFORMED BY

Lisa Bancroft, DVM

HOSPITAL NAME

Treasure Coast Animal
Emergency

REFERRING VET

Dr Angela Cail

INVOICE

303720

DATE

12/30/22

Gastrointestinal

Normal appearance of the gastro-esophageal junction, stomach, duodenum, small intestine, ileo-cecal junction, and colon with no loss of layering, normal wall thickness (duodenum 0.38 cm, jejunum 0.33 cm, colon 0.21 cm) and peristalsis, and no distension of the lumen.

Pancreas

Normal size (0.7 cm) and echogenic appearance. Regular capsule. Normal echogenic appearance of the mesentery and fat surrounding the pancreas.

Free Abdomen

No mesenteric lymphadenomegaly.
No ascites.

ULTRASONOGRAPHIC FINDINGS

Primary findings:

- Cystitis with thickening of the bladder wall and polyps.
- Uroliths.
- Hepatopathy.
- Hepatic nodule.

Secondary findings:

- Gall bladder sediment.

INTERPRETATION OF THE FINDINGS & FURTHER RECOMMENDATIONS

Etiologies for the urinary bladder would be chronic bacterial cystitis, secondary to the uroliths, polyploid cystitis, and neoplasia.

Etiologies for the hepatopathy would be reactive, hyperplasia, nodular hyperplasia, chronic hepatitis, and infiltrative neoplasia.

Etiologies for the hepatic nodule would be nodular hyperplasia, granuloma, organized hematoma or abscess, and neoplasia.

Further assessment would be urinalysis, urine culture, BRAF assay, catheter-assisted aspirate/biopsy of the urinary bladder wall, and FNA cytology of the liver.

Specific therapy would be dependent on an etiological diagnosis. Although the uroliths can be surgically removed, excision of the polypoid region does not appear feasible as there is involvement of the trigone.



PATIENT

Leilah Beber

SPECIES

Canine

BREED

Havanese

SEX

FS

AGE

8 years

WEIGHT

20 #

INTERPRETED BY

Remo Lobetti, BVSc,
 MMedVet (Med), PhD,
 Dipl. ECVIM

IMAGING PERFORMED BY

Lisa Bancroft, DVM

HOSPITAL NAME

Treasure Coast Animal
 Emergency

REFERRING VET

Dr Angela Cail

INVOICE

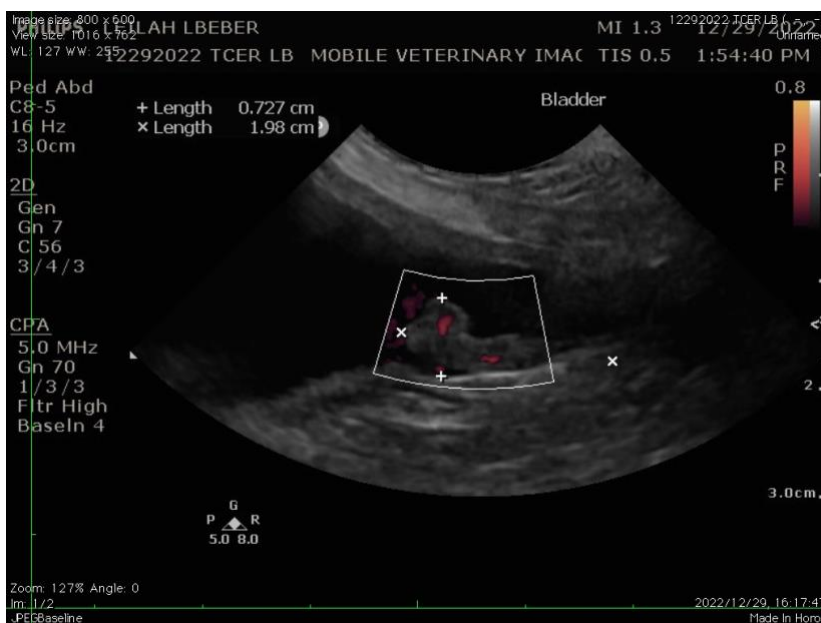
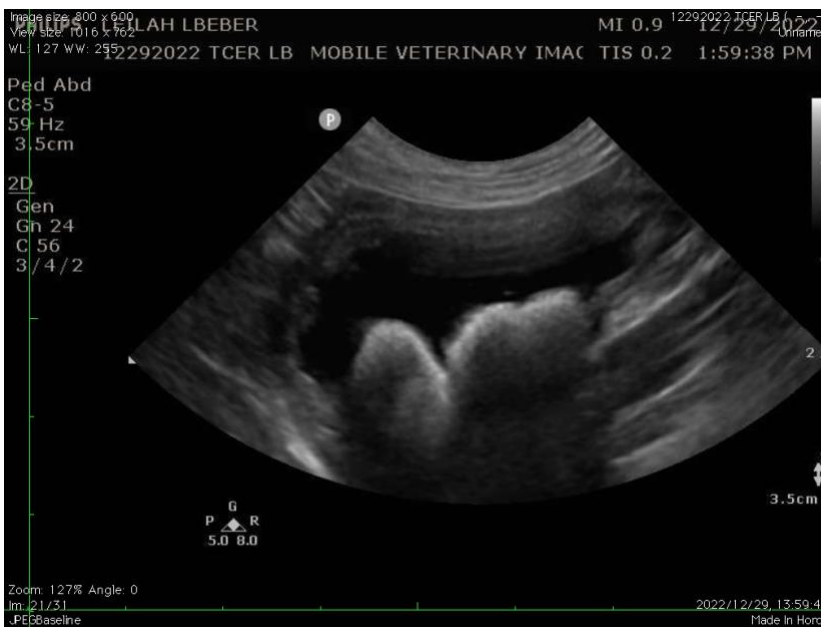303720

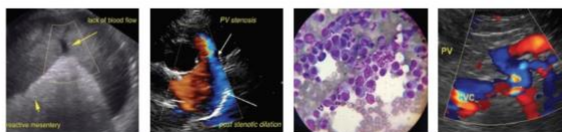
DATE

12/30/22

IMAGES

Urinary bladder





PATIENT **Liver**

Leilah Beber

SPECIES

Canine

BREED

Havanese

SEX

FS

AGE

8 years

WEIGHT

20 #

INTERPRETED BY

Remo Lobetti, BVSc,
 MMedVet (Med), PhD,
 Dipl. ECVIM

IMAGING PERFORMED BY

Lisa Bancroft, DVM

HOSPITAL NAME

Treasure Coast Animal
 Emergency

REFERRING VET

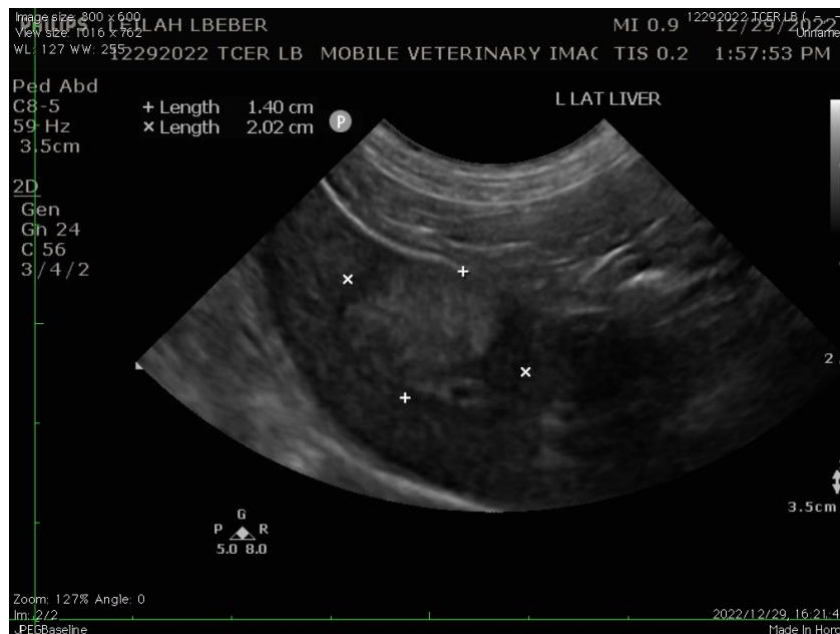Dr Angela Cail

INVOICE

303720

DATE

12/30/22



The information and recommendations provided are based on the images presented by the referring veterinarian. No evaluation can be communicated regarding pathology that was not visible in the image/video clips provided.

Thank you for this referral. If the clinical or image interpretation does not parallel your findings or if I can be of any further assistance please contact me.

Remo Lobetti, BVSc, MMedVet (Med), PhD, Dipl. ECVIM (Internal Medicine)
 rlobetti@mweb.co.za